

Original Article

Cheiloscopy and Palatoscopy: A Novel Tool for Sex Identification

Dr. Sheetal Mujoo*, Sakarde S**, Sur J***, Singh A****, Khan F*****, Jain S*, Deeplaxmi R*

*P.G Student, **Ex Professor and H.O.D, ***Reader, *****Senior Lecturer, Department of Oral Medicine & Radiology, Rungta College of Dental Sciences (RCDS), ****Research Director, Rural Dental Society for Oral Disease Prevention and Cure, Lucknow.



Dr. Sheetal Mujoo is pursuing her second year post graduation in OMRD department and actively involved in research work under guidance of her department head. She has presented papers at national and state level Specialty conferences. She has received best paper presentation award twice at national level specialty conferences.

Corresponding author - Dr. Sheetal Mujoo (sheetalmujoo@yahoo.co.uk)

Abstract

Oral and peri oral structures offer a myriad of possibilities in Forensic identification. The importance of dental identification is on the increase year after year. With the passage of time, the role of Forensic Odontology has increased as often teeth and dental restorations are the only means of identification. However, they cannot always be used; sometimes it is necessary to apply different and less known techniques.

Material & Methods: In this study, we analyzed the lip print and palatal rugae pattern in males and females using a classification given by Suzuki and Lysell respectively.

Results: Lip prints and rugae pattern are distinct for an individual. Type 1 and 1' lip pattern were predominantly seen in female subjects while Type 4 and 5 were commonly seen in males. No statistical significant difference was observed in the length of rugae between males and females. A statistically significant prevalence of curve & wavy form were seen in males and straight pattern in females.

Conclusions: Chelioscopy and palatoscopy can be useful in identifying the gender of the person by studying the pattern left at the crime scene.

Key-words: Forensic dentistry, Chelioscopy, Palatoscopy, Sex determination.

Chettinad Health City Medical Journal 2012; 1(4): 146 - 150

Introduction

Forensic identification by its nature is a multidisciplinary approach relying on positive identification methodology as well as presumptive or exclusionary methodologies which deals with proper handling and examination of dental findings.¹

Fingerprints and DNA finger printing have been successful in personal identification in the field of forensic science.² Just as in these method, lip prints can be instrumental in identifying a person positively and can be used to verify the presence or absence of a person at the scene of crime.³ External surface of lip has many elevations and depressions forming a characteristic pattern called lip prints, examination of which is referred to as cheiloscopy (cheilos means lips and skopien means see, in Greek) or lip print analysis.⁴ The approach is very similar to that of finger print analysis. The pattern of lip print is unique to an individual; hence used in forensic personal identification.

In 1902, the biological phenomenon of systems of furrows and prints on the human lips was first noted and described by anthropologist R.S Fischer. However, until 1950's they were not assumed to have any forensic use. In 1970, Suchihashi Y.T and Suzuki.T examined persons lip prints at the department of Forensic Odontology at Tokyo University and established that

the arrangement of lines and prints on the lips is individual and unique for each human being.^{3,5}

Palatoscopy is the name given to the study of palatal rugae in order to establish person's identity. Palatal rugae are anatomical folds called "plica palatine", the irregular connective tissue located on the anterior third of the palate behind the incisive papilla. As they are stable landmarks, once formed do not undergo any change except in length (due to normal growth) and remain in position throughout person's life. The use of palatal rugae was suggested as one of the method of identification in 1889 by Harrison Allen.⁶ The term "Palatal rugoscopy" was proposed in 1932, by a Spanish investigator named Trobo Hermosa.⁷ In 1937, Carrea conducted a detailed study and established a method to classify palatal rugae.⁸

Palatal rugae are well protected from trauma by their internal position in the oral cavity and they are insulated from heat by lips, tongue, and buccal fat pads.⁹ It is well established fact that rugae retains its shape throughout life and resist decomposition. Personal identification is based on the rugae pattern since the palate would remain intact when most other anatomical structures are destroyed, burned or dehydrated and also in situations where there are no finger prints.

The aim and objective of this study is to ascertain the use of lip pattern and palatal rugae pattern in identification and sex determination.

Materials and Methods

A total of randomly selected 80 subjects comprising of 40 males and 40 females, were selected, their age ranging between 18-35 years. All the participants were briefed about the purpose of the study and written consent was obtained from each of the participant.

Inclusion criteria

- Subjects above the age of 18 years
 - Lips free from any pathology, having absolutely normal transition zone between mucosa and skin were included in this study.
 - Palate free from any pathology and deformity.
- ### Exclusion criteria
- Subjects with congenital abnormalities /malformation.
 - Subjects with surgeries like orthognathic or operation for cleft palate, bony and soft tissue protuberance, active lesions, deformity of scars and trauma to the palate.
 - Subjects allergic to impression material or hypersensitive to lipstick.

Cheiloscopy: Materials used was

- Brown and red colored lipstick.
- Cellophane tape.
- White bond paper.
- Magnifying lens.

The subjects were asked to clean his/her lips with water and dry them with tissue paper. The subjects were asked to open the mouth and a dark colored frosted lipstick was uniformly applied on the lips up to the vermilion border. Then, the glued portion of cellophane tape strip was placed over the lips and the subjects were asked to make a lip impression in the normal rest position of the lips by dabbing it in the centre first and then pressing it uniformly towards the corner of the lips; The cellophane strip was carefully lifted from the lip from one end to the other, avoiding any smudging of the print. The cellophane strip was then stuck to the white bond paper for permanent record purpose and then analyzed using magnifying lens by three observers. The observers were blinded about the identification and sex of the subjects.

At the time of analysis, the middle part of lower and upper lip was taken as study area in accordance with Sivapathundaram et al. depends on superiority of properties of the lines on this study area. We followed the classification of lip patterns proposed by Tsuchi-hashi (1970), which is the most widely used classification in literature.¹⁰

Type1 : clear cut vertical grooves that run across the lips

Type 1' : similar to type 1, but do not cover the entire lip

Type 2 : branched grooves

Type 3 : intersected grooves

Type 4 : reticular grooves

Type 5 : grooves do not fall any of the type 1-4 and cannot be differentiated morphologically.

Palatoscopy: Materials used was

Alginate impression material

Dental stone

Graphite pencil 0.5

To record palatal rugae, alginate impression of maxillary arch was made and poured with dental stone and casts were preserved for interpretation. The rugae pattern on all the casts was delineated using a sharp graphite pencil under adequate light. The three observers were blinded about the identification and sex of the casts. The information obtained were recorded which included shape and size of the rugae.

A) The rugae pattern was then analyzed on these casts using the classification by Lysell (1955).¹¹ The rugae were classified based on their size of length as

- Primary: 5mm or more
- Secondary: 3 to 5 mm
- Fragmentary: 2 to 3 mm

B) The rugae were divided into four types based on their shape as

- A= curved
- B= wavy
- C= straight
- D= circular

The three observers were blinded about the identification and sex of the casts. The z-test was applied for the statistical analysis with p value < 0.05.

Results

Lip print

After the interpretation of lip print pattern, it revealed

1. We observed that no two lip print patterns matched with each other (Figure 1)
2. Type 1 and 1' lip pattern were predominantly seen in female subjects
3. Type 4 and 5 were commonly seen in males. This finding is statically significant with P value 0.05 (Table 1).
4. Out of 80, 36 females were correctly recognized as females and 38 males were correctly identified on the basis of lip print.

Palatal rugae

- In this study, we also observed that palatal rugae pattern of all 80 subjects (Figure 2) were distinct and unique.
- There was no difference in length of rugae between males and females (Figure 3) which was statistically insignificant.
- The predominant shape in males was wavy and curved form followed by straight pattern. (Table 2). The circular shape was rare. In females, the straight pattern was predominantly seen followed by wavy and curved pattern.
- In females, prevalence of Type 1 and Type 1' Lip pattern with straight form of palatal rugae were seen and In males, predominantly Type 4 and Type 5 Lip pattern with curved and wavy form of palatal rugae was seen

The Z-test was applied to test the significant difference between males and females for different types of lip print pattern, which showed a significant difference for lip pattern 1, 1' and 4, 5 type (with $P < 0.05$).

Applying same test for palatal rugae pattern, a statistically significant prevalence of curve and wavy form was seen in males followed by straight pattern in females.

Discussion

The positive identification of living or deceased persons using the unique traits and characteristics of the teeth and jaws is a corner stone of forensic science. The theory of uniqueness is a strong point used in the analysis of fingerprints and bite marks to convince the court of law. Likewise, even lip prints and palatal rugae patterns are considered to be unique to an individual and hence hold the potential for identification of an individual.¹²

If the gender of an individual is known,¹³ it is easier to shortlist the array of suspect for a particular crime. The present study was able to show that lip prints had the potential to identify gender. Although the results obtained in the present study do not prove the method to be infallible, it shows promise in being one more step to get to the truth. Lip prints thus have the potential of being a supplementary tool along with other techniques as a means of reorganization an individual gender. In our study population, Type 2 lip pattern was more frequently found, this finding is in accordance with the studies done in Indian and Chinese population by Manipady et al,¹⁴ while in other studies done by Shivapathsundaram et al¹⁵ in Indo-Dravidian population and by Vahanwala et al¹⁶ in Mumbai population, Type 3 and Type 1 pattern was more common respectively. This difference might be due to Geographical and racial differences.

In this study, we also found that no two lip print patterns matched with each other, establishing the uniqueness of lip prints and is supported by Preethi et al (2007)⁸ and Satyanaryana et al (2011).¹²

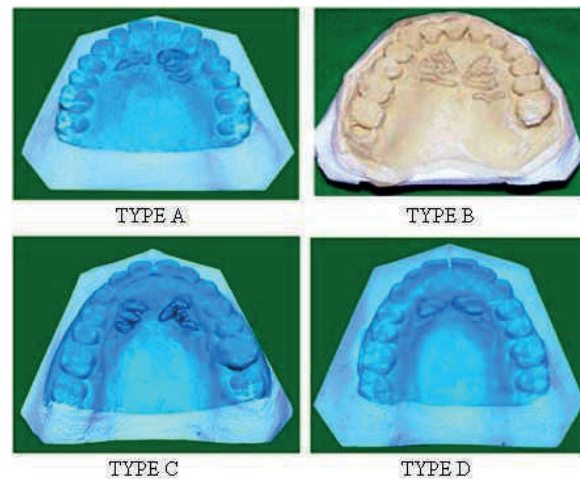


Fig1. Diagnostic cast showing different rugae pattern.



Fig2. Different Lip prints recorded in the given study.

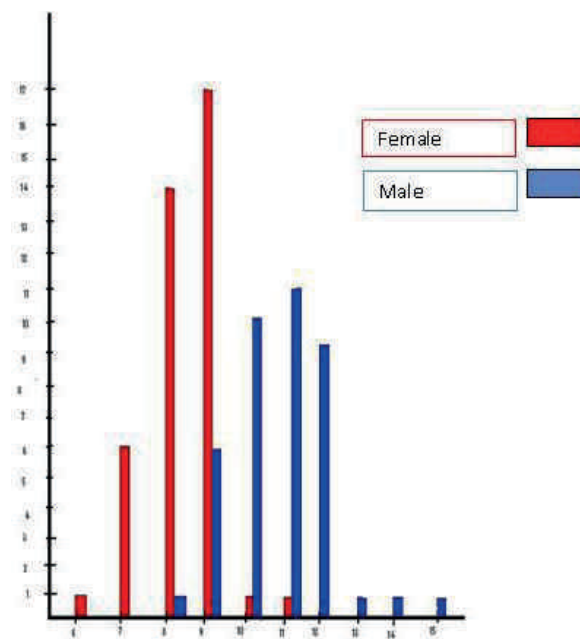


Fig3. Graphical representation of length of rugae in Males and Females.

Table 1: Z test to test the difference in lip print pattern between male and female subjects

Lip print pattern	Males	Females	Z- cal	Z tab		P value
				0.05	0.01	
1	5	11	-1.68	1.96	3.58	<0.01, <0.05
2	0	19	-4.99	1.96	3.58	<0.01, <0.05
3	15	4	2.89	1.96	3.58	>0.01, >0.05
4	8	2	2.03	1.96	3.58	>0.01, >0.05
5	10	4	1.77	1.96	3.58	>0.01, <0.05
6	2	0	1.43	1.96	3.58	>0.01, <0.05

Note:- P>0.05 (Not significant); p<0.05 (Significant) at $\alpha = 5\%$ level of significance

Table 2: Z test to test the difference in shape of rugae between male and female subjects.

Rugae Shape	Males	Females	Z- cal	Z tab		P value
1	23	15	1.79	0.05	0.01	<0.01, <0.05
2	14	8	1.50	1.96	3.58	<0.01, <0.05
3	3	16	-3.42	1.96	3.58	<0.01, <0.05
4	0	1	-1.01	1.96	3.58	<0.01, <0.05

Note:- P>0.05 (Not significant); p<0.05 (Significant) at $\alpha = 5\%$ level of significance

On one hand, Type 1 and 1' were predominantly seen in female subjects and this is in accordance with the study done by Preeti et al (2007),⁸ Satyanaryana et al¹² and Harpreet et al (2011)² while on other hand, Type 4 and 5 were more commonly seen in males and is similar to the findings of Preeti Sharma et al (2007).⁸ This finding establishes the uniqueness of lip pattern between genders. Due to anatomical position, it is unlikely that the study of palatal rugae could be used in the process of linking a suspect to a crime scene. On the other hand, palatoscopy may be used as a necro-identification technique.

There are different ways to analyze the palatal rugae. Intraoral inspection is probably the most used and economical method. However, this can create difficulties if a future comparative review is required. A more detailed and accurate and the need to preserve evidence may justify the use of photographs or impressions.³ while observing the shape of the rugae is a subjective process; it is relatively easy to record and does not require complex instrumentation. In this study, we observed that palatal rugae pattern of all 80 subjects were distinct and unique. None of the patterns were identical and also no bilateral symmetry was observed. This finding is in congruity, with results obtained in the studies conducted by English WR (1988),¹⁸ Indira AP et al,¹ Preethi et al (2007).⁸

In this study, curve and wavy form were predominantly seen in males and straight pattern in females which is similar to the findings of previous study conducted by Nayak et al on Indian populations,¹³ Valeria et al (2009) in Chile.¹⁷ However, no statistical difference was found

in the length of rugae between males and females, this is similar to the studies conducted by Shetty et al (2005).¹⁸

Conclusion

In forensic odontology, cheiloscopy and palatoscopy is upcoming technique for human identification. Few studies using palatal rugae as a means of forensic identification are found in literature. However, the idea of rugae being unique to an individual is promising and deserves further investigation. The day is not far when cheiloscopy and palatoscopy will be considered important forms of transfer evidence, and shall compliment fingerprints for identification of individual and sex determination.

References

- 1) Indira AP, Gupta M, David M. Rugoscopy for establishing individuality. *Ind J of Dental Advancement* 2011; 3(1): 427-433.
- 2) Singh H, Chhikara P, Singroha R. Lip prints as evidence. *J Punjab Acad Forensic Med Toxicol* 2011; 11(1): 23-25.
- 3) Utsuno H, Kanoh T, Tadokoro O, Inoue K. Preliminary study of Postmortem identification using lip prints. *Forensic Sci Int* 2005; 149: 129-132.
- 4) Goonerathne I. Establishing lip print analysis /

- cheiloscopy in Sri Lanka and its forensic use. Sri Lanka Journal of Forensic Medicine, Science and Law 2010; 1(1):28-9.
- 5) Patnaik V, Gopichand V, Kaushal S, Kaur G. Personal identification using Lip Prints (cheiloscopy) - a study in 500 punjabi females. Journal Indo-Pacific Academy of Forensic odontology 2010; 1(2): 20- 22.
 - 6) Nayak P, Acharya AB, Padmini AT, Kaveri H. Differences in the Palatal Rugae shape in two populations of India. Archives of Oral Biolo 2007; 52:977-82.
 - 7) Bansode S, Kulkarni M. Importance of palatal rugae in individual identification. Journal of Forensic Dental Sciences 2009; 1(2): 77-81.
 - 8) Sharma P, Saxena S, Rathod V. Cheiloscopy and Palatoscopy in Human Identification. Ind J Dent Res 2009; 20(4): 453-57.
 - 9) Ohtani M, Nishida N, Chiba T, Fukuda M et al. Indication and Limitation of using palatal rugae for Personal Identification in Edentulous Cases. Forensic Science International 2008; 176: 178-82.
 - 10) Tsuchihashi Y. Studies on Personal Identification by means of Lip Print. Forensic Sci Int 1974; 3(1):233-48.
 - 11) Lysell L. Plicae Palatinae transverse and Papilla incisive in man: A Morphologic and Genetic Study. Acta Odont Scand 1955; 13(1):135-37.
 - 12) Saxena S, Sharma P, Gupta N. Experimental studies of Forensic Odontology to aid in the Identification process. Journal of forensic dental sciences 2010; 2(2): 69-76.
 - 13) Naik SK, Prabhu A, Nargund R. Forensic Odontology: Cheiloscopy. Hongkong Dent J 2010; 8(1):25-28.
 - 14) Verghese A, Somasekar M, Babu U. A Study on Lip Print Types among the people of Kerala. J Indian Acad Forensic Med 2010; 32(1): 6-7.
 - 15) Sivapathasundharam B, Prakash P, Sivakumar G. Lip Prints(Cheiloscopy). Indian J Dent Res 2001; 12(4): 234-237.
 - 16) Vahanwala SP, Parekh DK. Study of lip prints as an aid to Forensic Methodology. J Ind Dent Assoc 2000; 17(1): 12-18.
 - 17) Venegas V, Valenzuela J, Lopez M et al. Palatal Rugae: Systemic Analysis of its Shape and Dimensions for Use in Human Identification. Int J Morphol 2009; 27(3): 819-25.
 - 18) Shetty K, Kalia S, Patil K et al. Palatal Rugae Pattern in Mysorean and Tibetan population. Ind J Dent Res 2005; 16(1):51-5.

Dopplegänger!

Everyone loves high density lipoprotein (HDL) as it protects us against the largest killer - the cardiovascular disease. That is why we call it "good" cholesterol. But the problem with something being so good is that even some undesirable elements begin to covet it. Actually the lymphoma cells love HDL so much that they cannot survive without it. Can their weakness be their downfall? Researchers at Northwestern Memorial Hospital think it is. They have developed HDL gold nanoparticle that behaves like a Dopplegänger (double or look-alike). It looks like HDL but once it is taken up by the lymphoma cell, deprives the cell of its nourishing morsel (HDL) by blocking its uptake. In trials, this nanoparticle without drugs has proved as effective as the chemotherapeutic agents.
(www.northwestern.edu/newscenter/)

- Dr. K. Ramesh Rao