

Review Article

Pigmented Lesions Of The Oral Cavity-Review And Differential Diagnosis

Dr.K.Sasireka***, Dr.V.Sivakumar***, Dr.Bobby Kurian**, Ms.Aneeshya Jose *

***Professor, Chettinad Dental College and Research Institute, Chennai, India, **Reader,*CRRI, Adiparasakthi Dental College and Hospital, Melmaruvathur, Tamil Nadu, India.



Prof. Dr. K. Sasireka M.D.S graduated B.D.S from Raja Muthiah Dental College, Annamalai University in the year 1987 and M.D.S in the year 1993 from the same institution. At present working as Professor and HOD, Department of Periodontics in Adiparasakthi Dental College and Hospital, Melmaruvathur.

Corresponding author - Dr.K.Sasireka (smilinganeeshya11@gmail.com)

Chettinad Health City Medical Journal 2014; 2(2): 48 - 51

Abstract

Pigmented lesions are commonly found in the mouth. Such lesions represent a variety of clinical entities, ranging from physiologic changes to manifestations of systemic illness and malignant neoplasm. Evaluation of patient presenting with a pigmented lesion should include a full medical and dental history, extra oral and intra oral examinations and in some cases biopsy and laboratory investigations.

Key words : Diagnosis, Differential diagnosis, Oral cavity, Pigmentation disorders.

Introduction

Pigmented lesions are commonly found in the mouth. Such lesions represent a variety of clinical entities, ranging from physiologic changes (racial pigmentation) to manifestations of systemic illness (Addison's disease) and malignant neoplasm (Kaposi's sarcoma).

Oral pigmentation may be exogenous or endogenous in origin. Exogenous pigmentations are commonly due to foreign body implantation in the oral mucosa. Endogenous pigments include melanin, haemoglobin and carotene. Melanin is produced by melanocytes in the basal layer of the epithelium and is transferred to the adjacent keratinocytes via membrane bound organelles called melanosomes. Melanin is also synthesized by nevus cells, which are derived from the neural crest cells and are found in the skin and mucosa.

Pigmented lesions caused by increased melanin deposition may be brown, blue, grey or black depending on the amount and location of melanin in the tissues¹.

Diffuse and bilateral pigmentation

a) Physiologic pigmentation

It is common in the African, Asian, and Mediterranean populations². It is due to greater melanocyte activity rather than a greater number of melanocytes. Physiologic pigmentation develops during the first two decades of life. The colour ranges from light to dark brown (Fig.1.1).The attached gingiva is the most common intraoral site of such pigmentation where it appears as a bilateral, well demarcated, ribbon-like dark brown band. The pigmentation is asymptomatic and no treatment is required.

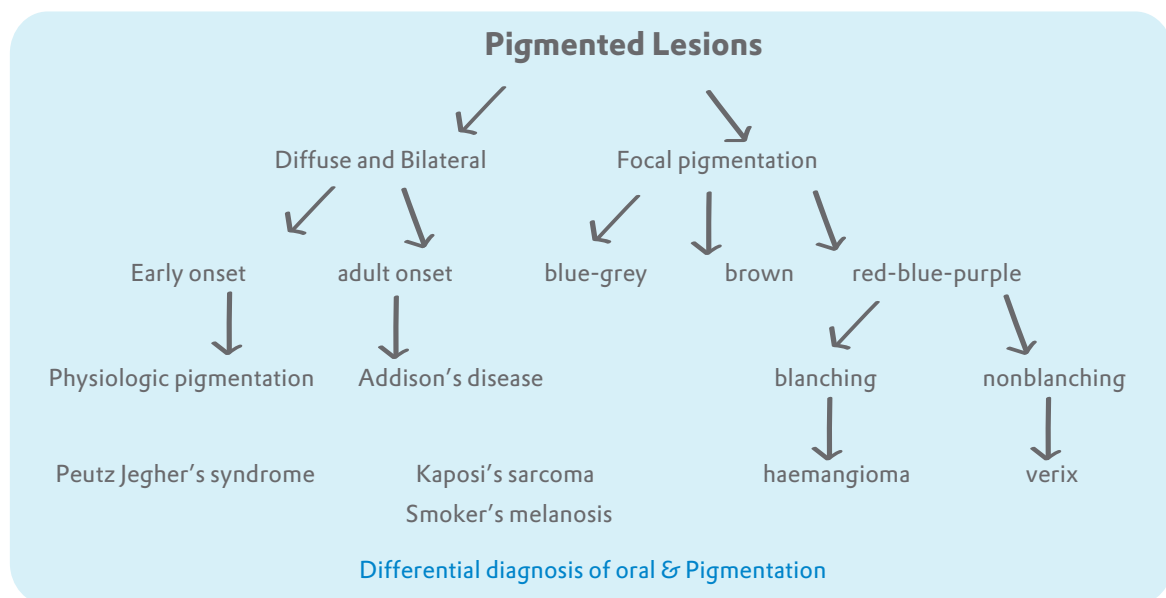

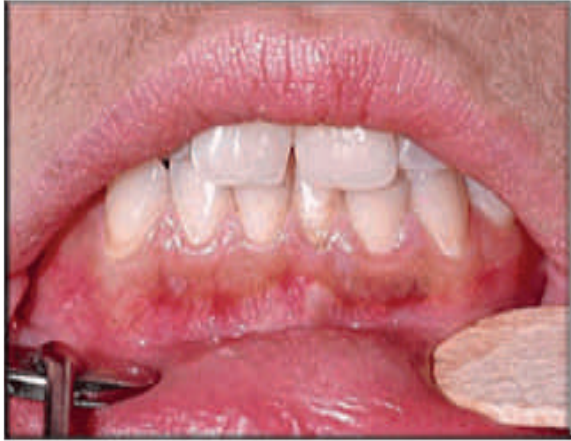


Fig.1.1: Physiologic pigmentation due to increased keratinisation

b) Addison's Disease

It is due to progressive bilateral destruction of the adrenal cortex by autoimmune disease, infection or malignancy. Oral involvement presents diffuse brown patches on gingival, buccal mucosa, palate and tongue which may resemble physiological pigmentation (Fig.1.2). Oral mucosal pigmentation associated with Addison's disease develops and progress during adult life and accompanied by weakness, nausea, vomiting, abdominal pain, constipation, weight loss and hypotension. Addison's disease can be fatal if left untreated. Management includes treatment of the underlying cause and corticosteroid replacement therapy.

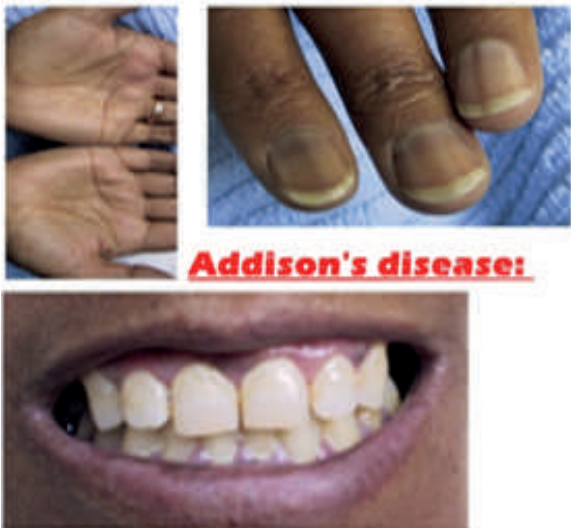

Fig 1.2: Diffuse pigmentation of the gingiva seen in Addison's disease

c) Drug – Induced Pigmentation

The pathogenesis of drug-induced pigmentation varies depending on the causative drug. Chloroquine (Fig.1.3) and other quinine derivatives are used in the treatment of malaria, arrhythmia and arthritis. Mucosal discolouration with this drug occurs as blue grey or blue black pigmentation in the hard palate³.

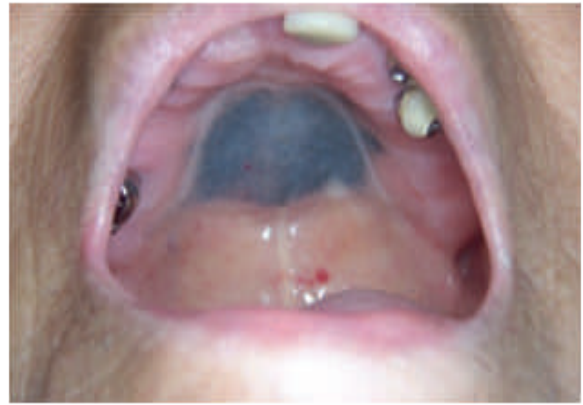

Fig.1.3: Bluish Grey pigmentation of the hard palate caused by antimalarial drug chloroquine.

d) Smoker's Melanosis

Smoking may cause oral pigmentation in light skinned individuals and accentuate the pigmentation of dark skinned persons⁴. Smoker's melanosis occurs in up to 25% of the smokers⁵. Women are more commonly affected than men, which suggest a synergistic effect between the female sex hormone and smoking. The brownish black lesions occur mostly on the anterior labial gingiva followed by buccal mucosa (Fig1.4). Smoker's melanosis usually disappears within three years of smoking cessation. Biopsy should be performed if there is surface elevation or increased pigment intensity or the pigmentation is in unexpected site⁴.

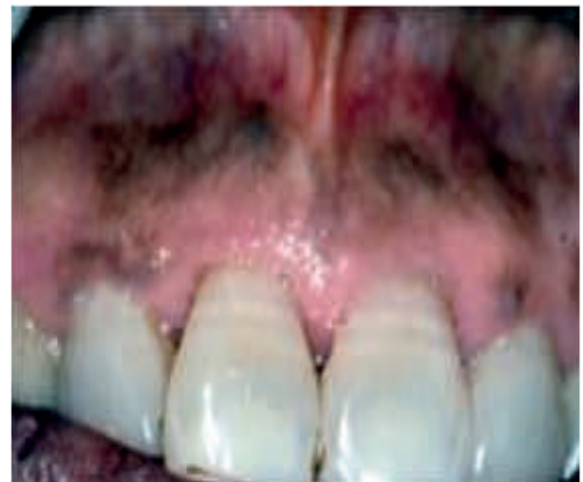

Fig.1.4: Brownish black hyperpigmentation of gingiva in smoker's melanosis.

e) Focal pigmentation Hemangioma

It is a benign proliferation of the endothelial cells that line the vascular channels. Haemangioma regresses as the patient ages, but vascular malformation persists throughout life. In the oral cavity tongue is the most common site of occurrence (Fig1.5). The lesion may be flat or slightly raised and colour varies from red to bluish purple depending on the type of vessels involved.

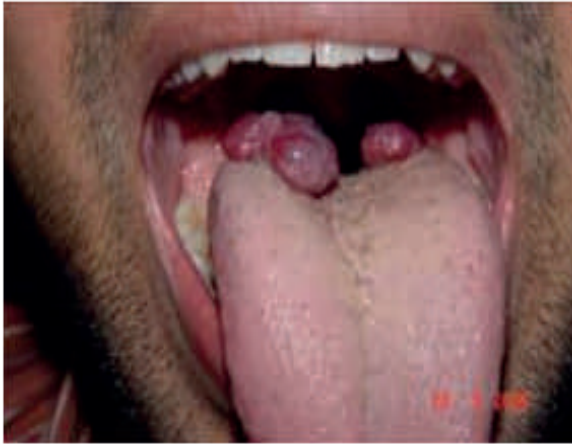

Fig. 1.5: Haemangioma of the tongue

f) Varix And Thrombus

Varices are abnormally dilated veins seen mostly in patients older than sixty years of age. The most common intra oral location is the ventral surface of the tongue where it appears as multiple bluish purple, irregular and soft elevations that blanch on pressure (Fig1.7). If a varix contains a thrombus, it presents as a firm bluish purple nodule that does not blanch on pressure. Thrombi are more common on the lower lip and buccal mucosa (Fig1.6).

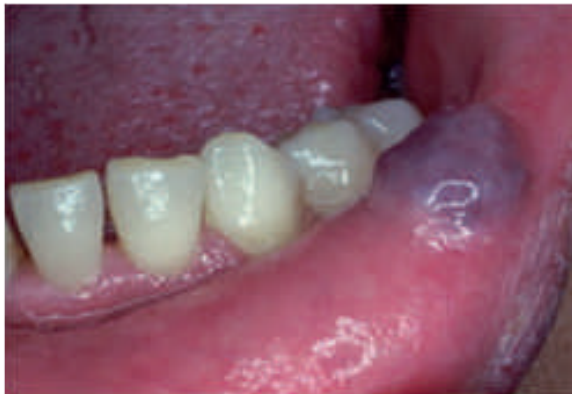

Fig.1.6: Thrombus present on the lower lip

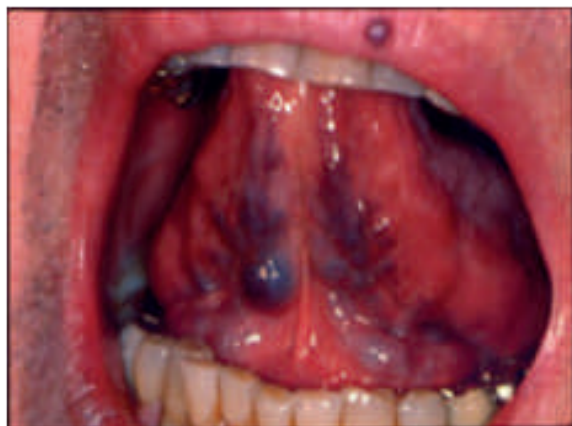

Fig.1.7: Varices present on the dorsum of the tongue.

g) Hematoma And Other Hemorrhagic Lesions

Hematomas, purpuras and ecchymoses are caused by extravasations of blood into the soft tissues. They appear as non blanching flat or elevated pigmented lesions (Fig1.8). They may occur spontaneously in certain systemic conditions such as idiopathic thrombocytopenic purpura or they may result from trauma. The colour produced by the degradation of haemoglobin to bilirubin varies among red, purple, blue and bluish black depending on the length of time. The colour gradually returns to normal, but takes upto two weeks. If hemorrhagic lesions occur in the absence of recent trauma, the patient should be investigated for platelet disorders and coagulopathies.

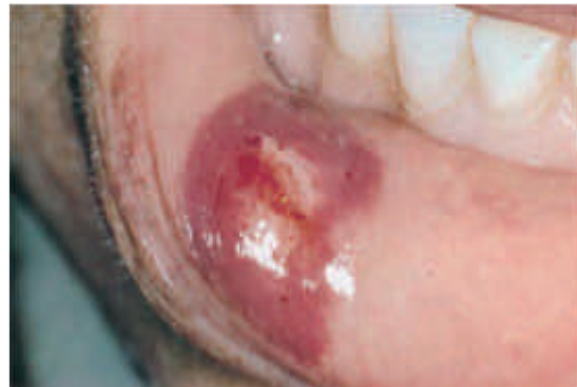

Fig.1.8: Hematoma of the lower lip.

h) Amalgam Tattoo

It is one of the most common causes of intra oral pigmentations. It presents clinically as a localized flat, blue-grey lesions of variable dimensions (Fig1.9). The gingival and alveolar mucosa are the most common sites of involvement. In some cases, when the amalgam particles are large enough, they can be seen in intraoral radiographs as fine radio-opaque granules. In these circumstances the diagnosis of amalgam tattoo can be made on the basis of the clinical and radiographic findings.

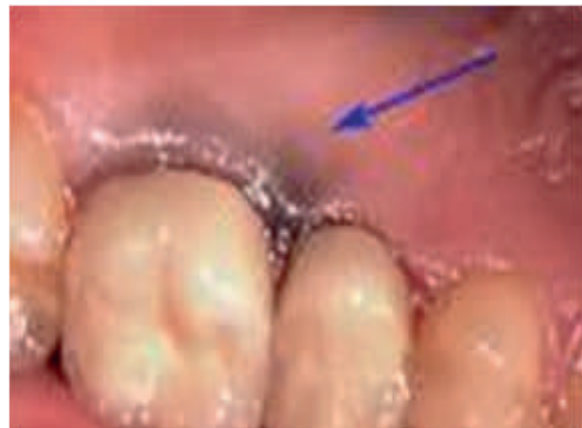

Fig.1.9: Blue grey hyperpigmentation of amalgam.

i) Pigmented Nevi

Pigmented nevi are rare causes of focal oral pigmentations. They present either brown or blue lesions (Fig1.10). As such they are classified as Junctional, Intradermal or Intramucosal and Compound nevi. These nevi may represent precursor lesions to oral mucosal melanoma. Thus these lesions should be excised and submitted for histopathologic examination⁵.

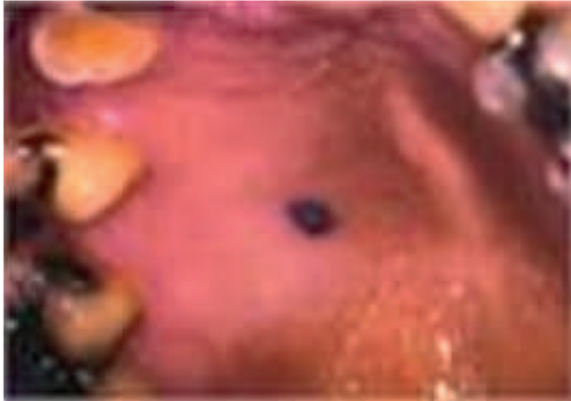

Fig.1.10: Blue nevi present on the palate.

j) Oral Melanoma

It is characterised by proliferation of malignant melanocytes along the junction between the epithelial and connective tissues as well as within the connective tissues. The most common site is the palate which occurs in about 40% of the cases followed by gingiva. Clinically, oral melanoma may present as an asymptomatic, slow growing brown or black patch (Fig.1.11) with asymmetric and irregular borders with ulceration, bleeding, pain and bone destruction.

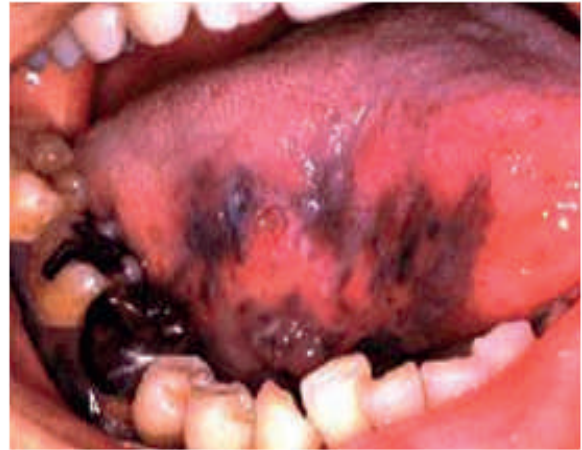

Fig.1.11: Oral melanoma of the tongue.

Conclusion

An algorithm of the pigmented lesions of the oral cavity is seen from physiologic changes to manifestations of systemic illness.

References

- 1) Elsen D. Disorders of pigmentation in the oral cavity (Clin Dermatol 2000) ; 18 (5) : 579-587.
- 2) Kleinegger CL, Hammond HL. Oral mucosal hyperpigmentation secondary to anti malarial drug therapy. Oral pathol Oral Radio 2000; 90 (2): 189-194.
- 3) Gaeta G, Satriano RA. Oral pigmented lesions. Clinical Dermatol 2002, 20(3) 286-288.
- 4) Hedik CA and Axell T. Oral melanin pigmentation in 467 Thai and Malaysian people with special emphasis on smoker's melanoma J. Oral path (1999); 20:(1-12).
- 5) Axell T and Hedin CA – Epidemiologic study of excessive oral pigmentation. Scand J Dent (1982) ; 90 (6) :434-442.

Culprit is Not the Age but a Protein!

The progressive loss of memory that afflicts the old is often considered to be an early sign of Alzheimer's. But age-related memory loss and Alzheimer's are two distinctive and clinically identifiable entities. They affect different parts of hippocampus: while Alzheimer's affects entorhinal cortex, the age related memory loss is due to changes in dentate gyrus. In a new study published online in the journal Science Translational Medicine (Sci Transl Med 28 August 2013 5:200ra115. DOI:10.1126/scitranslmed.3006373), the researchers from Columbia University Medical Centre (CUMC), analysed dentate gyrus and entorhinal regions in the post-mortem brain samples of eight individuals and found that age related memory loss was associated with decline in a histone binding protein RbAp48 in the dentate gyrus. When the researchers genetically inhibited RbAp48 gene in transgenic mice, the latter manifested memory deficits similar to those observed in the age related memory loss. The researchers feel that this study provides a conclusive evidence for separating age related memory loss as a distinct entity, apart from opening up opportunities for its therapeutic intervention.

- Dr. K. Ramesh Rao