

# Case Report

## Giant Dumb Bell Trigeminal Schwannoma

Dr.K.V.Karhikeyan\*, Dr.V.G.Ramesh\*\*

\*Consultant Neurosurgeon, \*\*Senior Consultant Neurosurgeon, Chettinad Super Speciality Hospital, Chennai, India.



Dr.K.V.Karhikeyan is currently working as Consultant Neurosurgeon at Chettinad Super Speciality Hospital. He completed his graduation in 2001 from the prestigious Madras Medical college and completed his MCH (Neurosurgery -5 yrs) from the Madras Institute of Neurology at Madras Medical college in 2007. He is very well trained in Micro neurosurgery and vascular neurosurgery. He joined our institute in 2010. He has special interest in Vascular Neurosurgery and Endoscopic Neurosurgery.

Corresponding author - Dr. K.V.Karhikeyan (surgenn@gmail.com)

### Abstract

Trigeminal schwannomas account for less than 8% of intracranial schwannomas and less than 0.4% of all intracranial tumors. They originate within the ganglion, nerve root, or 1 of the 3 divisions of the trigeminal nerve. About 50% of these tumors are limited to the middle fossa, while 30% extend into the posterior fossa and 20% are dumbbell-shaped and extend into both fossae. Dumb bell schwannomas pose a great surgical challenge in removing completely. Here we present such an interesting case.

**Key Words:** Trigeminal-Dumb bell-Retro sigmoid-Sub temporal

Chettinad Health City Medical Journal 2014; 3(1): 26 - 28

### Case Report

A 40 year old lady presented with history of dull persistent headache with right facial pain and numbness for 2 months duration. Patient also complained of giddiness and unsteadiness while walking for 1 month duration. On examination patient had normal higher mental function. Patient had right V1 V2 distribution diminished sensation with right partial Trigeminal motor involvement. Patient also had Right Grade 2 Facial Nerve involvement along with right cerebellar signs and cerebellar type nystagmus. No lower cranial nerve involvement and pyramidal tract involvement seen. MRI Brain with contrast showed Large Dumb bell shaped T1 Hypointense and T2 Hyperintense lesion arising in the middle cranial fossa at Meckel's cave extending into the posterior fossa via tentorial hiatus and occupying the right CP angle region, twisting and displacing the Brainstem and cerebellum (Fig.1). Anteriorly, the lesion extended upto superior orbital fissure. The lesion was well enhancing with contrast. Provisional diagnosis of Trigeminal Schwannoma TYPE C(Samii et al Classification)<sup>1</sup> considered. Since the posterior fossa component of the lesion was fairly big and cannot be removed through the Sub temporal approach, the tumor resection was planned in 2 stages. Trans petrosal approach was not considered because the patient's hearing was well preserved.

In stage 1 procedure the patient was placed in Park Bench position and through a Right retro sigmoid sub occipital approach the posterior fossa opened and CSF was let out, cerebellum became lax. There was a firm well encapsulated highly vascular lesion was seen projecting via the hiatus and pressing on the VII-VIII cranial nerve component. Careful arachnoid dissection and tumor debulking was done. Capsule was dissected meticulously under microscope from the surrounding Cranial nerves, vessels, cerebellum and brainstem. The

whole tumor was removed upto tentorial hiatus in this stage. Post operatively patient had partial Facial Nerve palsy and left Hemiparesis grade 4. Post op CT scan showed no residual lesion at posterior fossa and there was a small bleed in right half of brainstem. Patient hemiparesis recovered over 4 weeks.

In stage 2, procedure was performed after 4 weeks. Through a Right Sub temporal Extradural approach the middle cranial fossa part of the tumor was removed in total. There was a bony erosion at the medial part of Petrous bone through which the tumor was protruding into the posterior fossa. Post operative period uneventful. Post operative scan showed no residual lesion (Fig 2,3). At 4 weeks follow up patient was walking without support with residual Facial Nerve palsy which is also recovering. At 3 months follow up patient had minimal facial numbness and no Hemiparesis. Follow up Contrast MRI showed no residual lesion (Fig 4).

### Discussion

The trigeminal nerve emerges from the ventrolateral surface of the pons and runs anteriorly 1-2 cm through the cerebellopontine cistern to reach the petrous apex. Vascular structures such as the petrosal vein and the superior cerebellar artery lie close to the trigeminal nerve. Over the petrous apex, 7 mm of distance from the medial lip of the internal acoustic meatus, the Gasserian ganglion is enveloped by a dural deflection forming the Meckel's cave, laterally to the cavernous sinus and the carotid artery. As it leaves the Meckel cave, the trigeminal nerve is divided into 3 branches: the ophthalmic (V<sub>1</sub>), maxillary (V<sub>2</sub>), and mandibular (V<sub>3</sub>) branches. These 3 nerves run under the middle fossa dura mater and leave the temporal bone through the lateral wall of the cavernous sinus (for V<sub>1</sub>), foramen

The trigeminal nerve can also be surgically classified into 3 segments: cisternal, from the brainstem to the petrous apex; intracranial-extradural, from the Meckel cave to the foramina; and extracranial (V<sub>1</sub>, V<sub>2</sub>, and V<sub>3</sub>). Functionally, the trigeminal nerve has 2 portions: the "pars compacta," which constitutes the triangular portion and comprises the primary afferent fibers that are responsible for the special sensibility of the face; and the motor root, which carries the branchiomotor fibers to the muscles of mastication. The motor root runs practically separated from the "pars compacta" but together with the cranial portion of the nerve. At the level of the Meckel cave, it is oriented medially and leaves the skull together with the mandibular nerve.

The intracranial-extradural portions of V<sub>2</sub> and V<sub>3</sub> are surgically identified using the foramen spinosum as an anatomical landmark, which is located at the sphenoid bone and contains the middle meningeal artery. The foramina ovale and rotundum are located 2-5 mm superoanteriorly and 10-12 mm superomedially to the foramen spinosum, respectively.

Schwannomas originating from cranial nerves are usually benign, isolated, and slow growing. They may occur in multiple sites when associated with NF2. Schwannomas arising from the trigeminal nerves are the second most common type of intracranial schwannomas, representing 0.8-8% of these tumors. Trigeminal schwannomas tend to occur in middle-aged patients; the highest incidences are between the ages of 38 and 40 years, and are more common in women. Patients with TS frequently complain of trigeminal nerve-related symptoms, but they may also be asymptomatic. The clinical symptoms in these patients include trigeminal hypesthesia, facial pain, headaches, hearing impairment, seizures, diplopia, ataxia, and hemiparesis and increased ICP with papilledema.

Samii et al, classified the tumor extension into 4 categories based on radiological findings: Type A, intracranial tumor predominantly in the middle fossa; Type B, intracranial tumor predominantly in the posterior fossa; Type C, intracranial dumbbell-shaped tumor in the middle and posterior fossa; and Type D, extracranial tumor with intracranial extensions<sup>1</sup>.

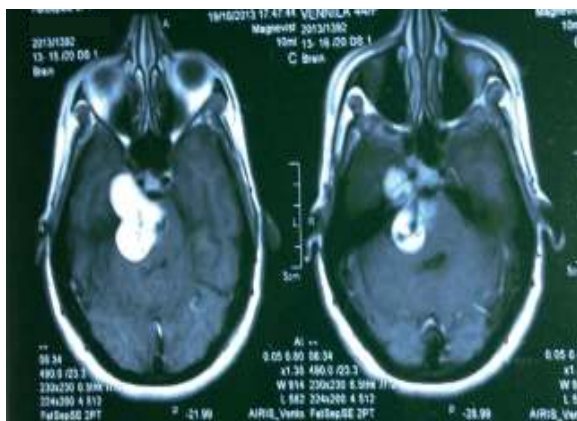


Fig 1: Contrast MRI Brain showing well contrast enhancing dumb bell shaped giant lesion arising from middle cranial fossa extending into posterior cranial fossa.

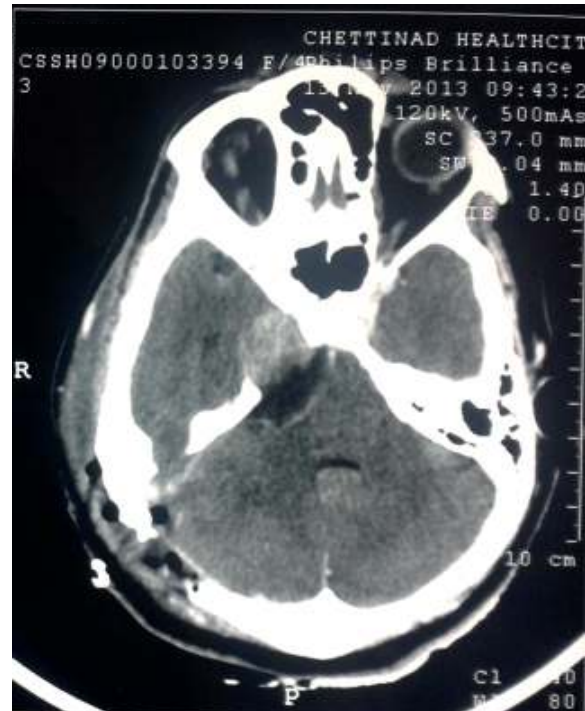

Fig 2: Post op Contrast CT after first stage showing complete excision of posterior fossa lesion and the remaining middle cranial fossa part

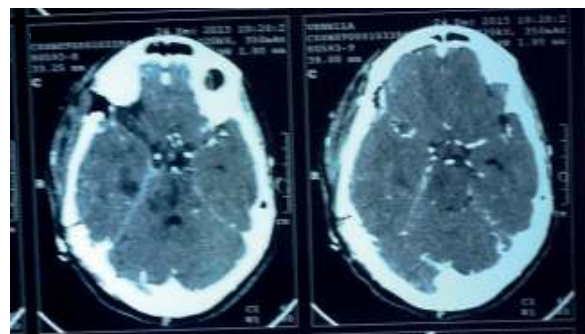


Fig 3: Immediate post op CT after second stage showing no residual lesion

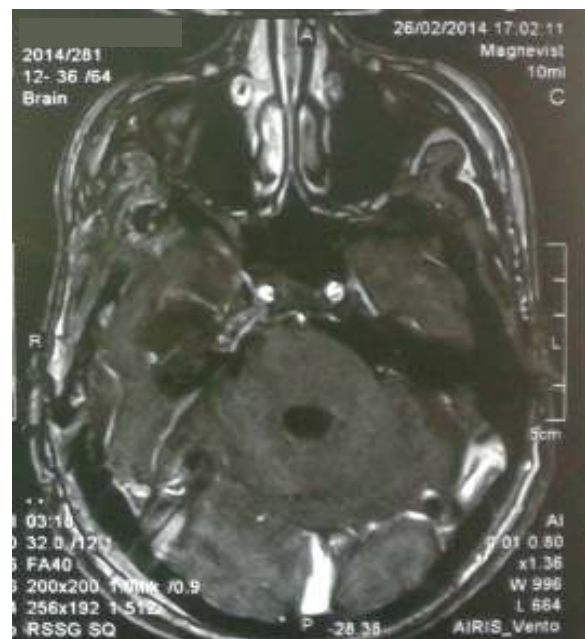

Fig 4: 2 months follow up Contrast MRI showing no residual lesion

Management strategy for TSs involves clinical observation followed by MR imaging follow-up for incidental tumors, surgical removal, and, alternatively, radiotherapy or radiosurgery. Complete or near-total surgical removal can be achieved in > 70% of the patients by means of skull base approaches and microsurgical dissection<sup>2,3,4,5</sup>. Involvement of the cavernous sinus is one cause of subtotal resection. In most cases, a clear plane of cleavage between the tumor capsule and the cavernous sinus structures can be found, allowing complete dissection and total resection. In the modern neurosurgical era, recurrence of TS is rare and the outcome is usually favorable; the most frequent symptom after surgery is trigeminal hypoesthesia, which is transient in most cases. Facial pain may persist after surgery, but most patients report improvement or total relief during follow-up. Diplopia, CSF leakage, meningitis, and hydrocephalus have been also described as possible complications. Most new cranial nerve deficits present resolution within 4-6 months.

Although good results have been reported with radiosurgery, this technique is reserved for small, Non resectable, and residual tumors within the cavernous sinus. Long-term follow-up of patients treated with this method is still needed to evaluate the exact role of radiosurgery in the late control of these lesions. It is evident, however, that no patient will ever be cured of this benign tumor with radiotherapy or radiosurgery<sup>6,7,8</sup>.

## Conclusion

Management of giant trigeminal schwannomas occupying multiple compartments is a challenging one. Since it is a benign tumor complete surgical excision should be done. Removing in single approach depends on the extent of the lesion and the neurological deficit.

## References

- 1) Samii M, Migliori MM, Tatagiba M, Babu R: Surgical treatment of trigeminal schwannomas. *J Neurosurg* 1995; 82:711-718
- 2) Trigeminal neurinomas extending into multiple fossae: surgical methods and review of the literature:Kazunari Yoshida, M.D., and Takeshi Kawase, M.D..Department of Neurosurgery, School of Medicine, Keio University, Tokyo, Japan
- 3) Al-Mefty O, Ayoubi S, Gaber E. J. Trigeminal schwannomas: removal of dumbbell-shaped tumors through the expanded Meckel cave and outcomes of cranial nerve function. *Neurosurg*. 2002 Mar;96(3):453-63.
- 4) Youssef S, Kim EY, Aziz KM, Hemida S, Keller JT, van Loveren HR. The subtemporal interdural approach to dumbbell-shaped trigeminal schwannomas: cadaveric prosection. *Neurosurgery*. 2006 Oct;59(4 Suppl 2):ONS270-7; discussion ONS277-8.
- 5) Yoshida K, Kawase T: Trigeminal neurinomas extending into multiple fossae: surgical methods and review of the literature. *J Neurosurg* 1999; 91:202-211
- 6) Hamm KD, Gross MW, Fahrig A, Surber G, Henzel M, Kleinert G, et al: Stereotactic radiotherapy for the treatment of nonacoustic schwannomas. *Neurosurgery* 2008; 62:29-36
- 7) Hasegawa T, Kida Y, Yoshimoto M, Koike J: Trigeminal schwannomas: results of Gamma Knife surgery in 37 cases. *J Neurosurg* 2007; 106:18-23
- 8) Pan L, Wang EM, Zhang N, Zhou LF, Wang BJ, Dong YF, et al: Long-term results of Leksell gamma knife surgery for trigeminal schwannomas. *J Neurosurg* 2005; 102:220-224