

# Case Report

## A Rare Presentation of Chronic Myeloid Leukemia

Mayilananthi K\*, Vishwanath C Naragond\*\*, Durga Krishnan \*\*\*, Rajasekaran D\*\*\*\*

\*Associate Professor, \*\*Post Graduate Student, \*\*\*Associate Professor, \*\*\*\* Prof. & HOD, Dept. of General Medicine, Chettinad Hospital & Research Institute, Chennai, India.



Dr. Mayilananthi has completed her M.D. from Madras Medical College. She is currently working as the Associate Professor in Chettinad Hospital & Research Institute, Chennai, India.

Corresponding author - Mayilananthi K ([mayilananthikaliannan@gmail.com](mailto:mayilananthikaliannan@gmail.com))

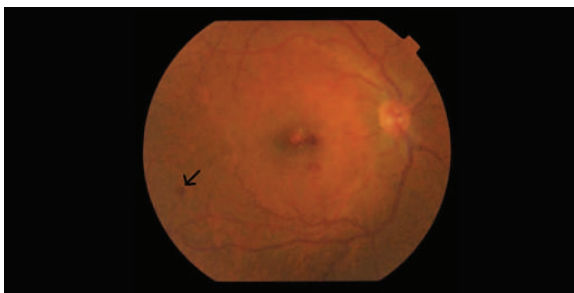
**Key Words:** Chronic myeloid leukemia, Roth spots  
Chettinad Health City Medical Journal 2014; 3(4): 198

### Introduction

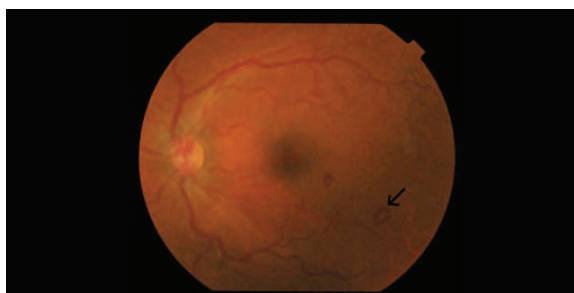
Chronic Myeloid Leukemia (CML) is a commonly encountered hematological malignancy, characterised by increase in erythroid, myeloid cells and platelets in the peripheral blood as well as marked myeloid hyperplasia in the bone marrow. The typical symptoms at presentation are fatigue, anorexia and weight loss, and the most common physical finding is splenomegaly. The presence of Philadelphia chromosome [t(9:22)] is the molecular abnormality found in 95% of patients. Imatinib, an inhibitor of BCR-ABL tyrosine kinase, is the standard treatment for chronic phase of CML<sup>1</sup>.

### Case Report

A 34 year old Indian male presented to ophthalmology department with bilateral progressive loss of vision of 5 days duration. Otherwise the patient was asymptomatic. No significant illness in the family. Fundus examination (Fig 1 & 2) showed bilateral white centred retinal haemorrhages (Roth spots). Hence patient was referred to medicine department for further evaluation. On physical examination he had pallor and massive splenomegaly. Examination of other systems was unremarkable.



**Fig 1** - Right fundus showing white centred haemorrhages



**Fig 2** - Left fundus showing white centred haemorrhages

His laboratory investigation revealed a haemoglobin of 8.8gm/dl with red cell count of  $2.6 \times 10^{12}/L$  and white cell count of  $2.85 \times 10^{11}/L$  (polymorphs 92%). His platelet count, ESR (12mm/hr) and urine examination were normal. The peripheral smear showed marked leukocytosis, basophilia and eosinophilia suggestive of chronic myeloid leukemia.

### Discussion

CML accounts for 15% of all leukemia<sup>1</sup>. It is a pluripotent stem cell disease characterized by anaemia, extreme blood granulocytosis and granulocytic immaturity, basophilia, often thrombocytosis and splenomegaly. CML usually presents with symptoms like easy fatigability, anorexia, abdominal discomfort, weight loss and excessive sweating. It rarely presents with isolated visual symptoms<sup>2</sup>.

Only 5-10% of patients in Chronic Myeloid Leukaemia present with eye involvement in the form of Roth spots, optic nerve oedema/pallor, retinal haemorrhage, retinal vein tortuosity, cotton wool spots and sea fan neovascularization<sup>3</sup>.

Other causes of Roth spots include subacute bacterial endocarditis, hypertension, diabetes, oral contraceptive use, systemic lupus erythematosus and multiple myeloma<sup>4</sup>. Subacute bacterial endocarditis is considered to be the commonest cause for Roth spots. However the presence of Roth spots should lead to search for other clinical condition such as leukaemia. We present this case for its rarity.

### References

- 1) Marshall A. Lichtman, William Joseph. Williams Hematology, 7th edition. 2006. McGraw-Hill Inc.
- 2) Blanka Doko Mandi, Vlatka Potonjak, Goran Beni, Zdravko Mandi, Ante Pentz, Tomislav Franjo Hajni. Visual Loss as Initial Presentation of CML. Coll Antropol. 2005;29(1): 141-143
- 3) Hung PK, Sanjay S. Visual disturbance as first symptom of chronic myeloid leukemia. Middle East Afr J ophthalmol 2011 Oct; 18(4):336-8.
- 4) Roland Ling, Bruce James: White-centred retinal haemorrhages (Roth spots) Postgrad Med J 1998; 74: 581-582