

Case Report

Soft Tissue Laser in The treatment of Granuloma Gravidarum

Aniz*, Dhivakar**, Saravanan***, Vishnu Prasad***

*Associate Professor, **Senior Lecturer, ***Reader, Dept. of Public Health Dentistry, Karpaga Vinayaga Institute of Dental Sciences, Chennai



Dr. Aniz has graduated from Rajah Muthiah Dental College, Annamalai University. He has done his Masters in Periodontology and Oral Implantology from Ragas Dental College, TN Dr. M.G.R University. His areas of interests are research and lasers. He is currently working as Associate Professor in the Department of Periodontics, Karpaga Vinayaga Institute of Dental Science. He has various publications to his credit.

Corresponding author - Aniz (anizmds@gmail.com)

Chettinad Health City Medical Journal 2015; 4(2): 105 - 107

Abstract

LASER has been a great boon in Periodontics. Soft tissue LASERS ensure greater hemostasis, bactericidal effect and minimal wound contraction than conventional surgery. Granuloma Gravidarum is a pyogenic granuloma that occurs during pregnancy with multi factorial aetiology. It is mostly painless and does not warrant prompt treatment and can be carried out post partum, however in cases with pain and loss of function excision is advised but the only challenge which remains is achieving hemostasis. This article consists of a case presentation of a 25 year old pregnant female patient in the third trimester with granuloma gravidarum who was successfully treated using soft tissue diode LASER (iLase)

Key Words: Pyogenic granuloma, Pregnancy, Diode Laser

History

The advent of LASER in the medical fraternity has revolutionized the field by leaps and bounds. It has a wide spectrum of advantages and uses ranging from achieving hemostasis to analgesia, it also ensures bactericidal action and offers comfort to the surgeon and the patient. Granuloma Gravidarum is a pyogenic granuloma that commonly occurs during pregnancy especially in the third trimester in the gingiva. The etiology is multi factorial, the hormonal imbalance¹ (i.e.) increased concentration of oestrogen and progesterone during pregnancy leads to rise in the level of Sub gingival microorganisms like *Prevotella intermedia*^{2,3} and Altered host response which increases the vascular permeability⁴ which favours the infiltration of fluids into the peri vascular tissue and in turn enhances the inflammatory response and plays an important role in the development of the lesion. The prevalence of granuloma gravidarum is seen in 5% of all pregnancies⁵.

Histologically it presents as a central mass of connective tissue, with numerous diffusely arranged, newly formed and engorged capillaries lined by cuboid endothelial cells as well as a moderately fibrous stroma with varying degrees of edema and chronic inflammatory infiltrate. The stratified squamous epithelium is thickened, with prominent rete pegs and some degree of intracellular and extracellular edema, prominent intercellular bridges, and leukocytic infiltration.

Case Presentation

A 24 year old female patient in the third trimester of pregnancy reported to the outpatient department of Periodontics, Karpaga Vinayaga Institute of Dental Sciences with the chief complaint of swelling with pain

and bleeding in the gums for the past one week in the left upper tooth region which enlarged slowly to attain the present size. On intra oral examination, a bright red, soft, friable and pedunculated mass approximately of size 1x1cm was found in the gingival between 23 and 24. Bleeding was seen on slight provocation. It was provisionally diagnosed as Granuloma gravidarum although treatment can be delayed post partum, the patient had excruciating pain and difficulty in mastication, Hence a surgical excision was planned. To minimize pain and bleeding excision with soft tissue diode laser was preferred to conventional excision.

Local Anaesthesia was administered by Local infiltration Labially and palatally, and excision was carried out by diode LASER Flap was elevated to gain access to the peduncle and it was removed along with the underlying granulation tissue. The area was debrided of local irritants and sutured using 3-0 black silk with interrupted sutures. A periodontal pack was placed to augment healing.

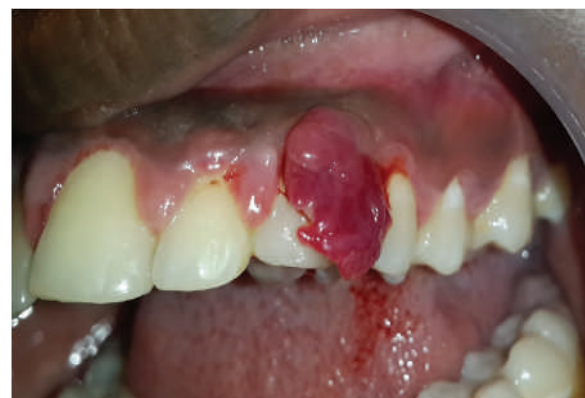

Fig 1- Pre operative view - Labial

The biopsy results showed stratified squamous epithelium with underlying fibro vascular connective tissue. The epithelium exhibits long and thin rete ridges and is compressed and atrophic in some areas. The underlying connective tissue is covered in fibrino purulent membrane in some areas. The connective tissue also shows numerous budding capillaries and dense inflammatory cells predominantly of lymphocytes and plasma cells suggestive of Granuloma Gravidarum.

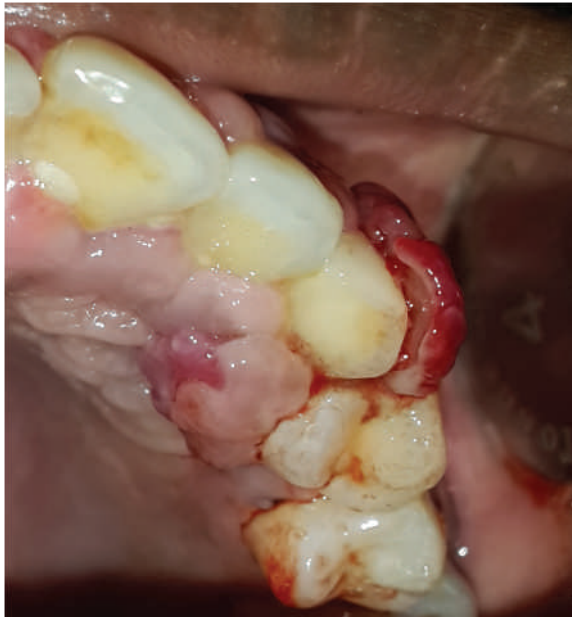

Fig 2- Preoperative view - occlusal

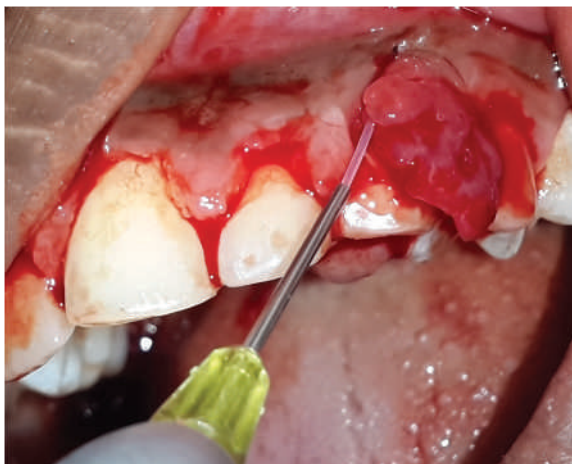


Fig 3- Excision using LASER

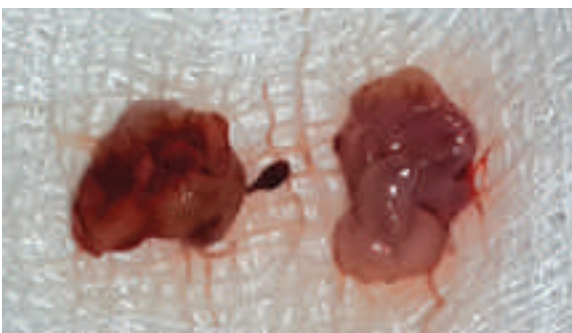


Fig 4- Excised Tissue

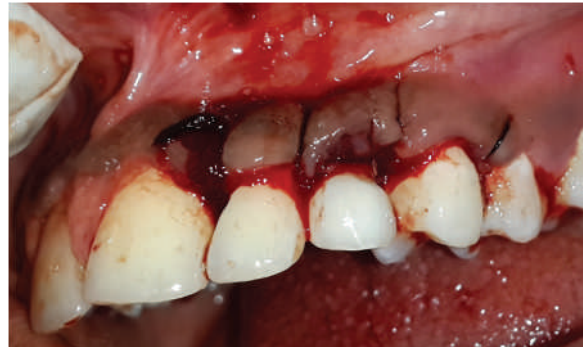

Fig 5 - Immediate Post op

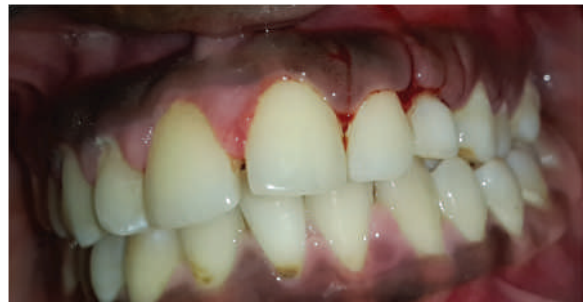

Fig 6 - Week Post operative

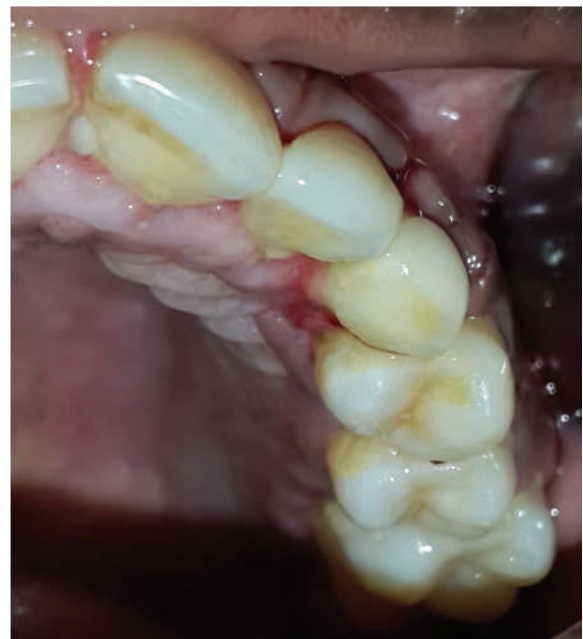

Fig 7 - 1 week Post operative

Discussion

Granuloma gravidarum also known as Pregnancy tumour is generally a painless enlargement seen in the gingiva during pregnancy. It may resolve by itself post partum but in some cases they are associated with pain and loss of function on such instances excision of the lesion is advised. However during conventional excision achieving Haemostasis stands as a huge challenge as the tumour is highly vascular, in such instances, Soft tissue Diode LASER stands as a viable alternative as excision using LASER cauterizes the blood vessels which ensures greater haemostasis in addition to bactericidal effect and minimal wound contraction.

References

- 1) Amar S, Chung KM: Influence of hormonal variation on the periodontium of women, *Periodontol* 2000;6:79.
- 2) Kornman KS, Loesche WJ: The subgingival flora during pregnancy, *J Periodontal Res* 1980;15:111.
- 3) Raber- Durlacher JE, van Steenberghe TJM, van der Velde U, et al: Experimental gingivitis during pregnancy and postpartum: clinical, endocrinological and microbiological aspects, *J Clin Periodontal* 1994;21:549.
- 4) Rafael Bragado, Elena Bello, Luis Requena, Guadalupe Renedo, Emma Texeiro, Mariâa Victoria Alvarez, Maria Angeles Castilla and Carlos Caramelo. Increased Expression of Vascular Endothelial Growth Factor in Pyogenic Granulomas. *Acta Derm Venereol* 1999; 79: 422 - 425.
- 5) Maier AW, Orban B: Gingivitis in pregnancy, *Oral surg* 1949; 2:334.
- 6) Azma E, Safavi N. Diode laser application in soft tissue oral surgery. *J Lasers Med Sci.* 2013 Fall;4(4):206-11.

Lowly Platelet Tracks Cancer!

Worldwide, cancer remains one of the most important causes of disability and death. Secret to its effective control lies in its early detection. Apart from exfoliative cytology and biopsy in certain types of cancers, all other available methods have proved less efficient in achieving that goal. If the results of a new study hold out, the solution may be at hand in near future. In that study, researchers from Umea University, used RNA from blood platelets to detect, locate and classify the tumours. Using just a drop of blood they were able to identify tumours with 96% accuracy. They were also able to decipher the origin of tumours in so far unrivalled accuracy of 71%. The days of more invasive diagnostic procedures like biopsy appear numbered (*Cancer Cell*, 2015; 28 (5): 666 DOI: 10.1016/j.ccell.2015.09.018)

- Dr. K. Ramesh Rao