

Case Report

Spontaneous Recanalization of an Occluded Internal Carotid Artery

Alexandra Matthews, Hansraj Riteesh Bookun, Andrew Cheng, Emily Stevens

Junior Doctor, The Geelong University Hospital, Geelong, Australia



My name is Alex Matthews and I am currently working as a Junior Doctor for Barwon Health in Geelong, Victoria. Throughout the course of my studies I have maintained an interest in surgery, critical care and pre-hospital medicine. Whilst rotating through different areas of the hospital environment I have enjoyed the variety of patient presentations and unusual cases across each speciality. In order to continue my learning and contribute in my field I aim to publish further studies of interest which will influence practice and improve patient outcomes.

Corresponding author - Dr. Hansraj Riteesh Bookun (riteesh.bookun@gmail.com)

Chettinad Health City Medical Journal 2016; 5(1): 48 - 51

Abstract

We describe here a case of spontaneous recanalization of a left occluded Internal Carotid Artery (ICA) on the background of a previous Carotid Endarterectomy (CEA) on the contralateral symptomatic side. This rare event with only anecdotal evidence describing its incidence and natural history was picked up with ultrasound scanning. Initially, only trickle flow was demonstrated and after 12 months, the stenosis in the left internal carotid artery was graded as less than 50% on ultrasound. Our report highlights the importance of following up carotid system lesions and contributes to the discussion of how such events should be managed.

Key Words: Internal Carotid Artery (ICA), Carotid Endarterectomy (CEA)

Case Report

Mr EL is a 70 year old man who presented to the Vascular Surgery Outpatient Clinic for routine surveillance of his carotid artery disease; having previously undergone a right CEA in June 2011. This was in the setting of a 70-79% symptomatic stenosis of the right ICA and an occluded left ICA. He suffered from a left middle cerebral artery territory stroke in January 2011. Mr EL maintains a complex past medical history including radical prostatectomy and abdominoperineal resection for bowel cancer. He also has regular surveillance for a 44mm infra-renal abdominal aortic aneurysm and is treated pharmaceutically for hypertension, hyperlipidaemia, and type 2 diabetes mellitus.

Mr EL is an ex-smoker with a 40 pack year history. He drinks moderate amounts of alcohol and lives independently with his wife. Mr EL was followed up 4 weeks post-operatively in July 2011. He underwent carotid ultrasound studies which demonstrated no stenosis in the right ICA and occlusion of the left ICA. He has since been followed up annually as an outpatient and has experienced no symptom of cerebral ischaemia. Routine ultrasound surveillance of the carotid arteries in July 2012 and August 2013 reported no change. However in August 2014 carotid ultrasound of the left ICA demonstrated a trickle of flow, while the right ICA remained unchanged. This new finding was discussed during clinic with the vascular consultant and repeat surveillance was arranged in 12 months' time.

Mr EL's latest carotid ultrasound study from August 2015, (50 months after contralateral surgical intervention) demonstrates that the left internal carotid artery is now open with <50% stenosis, while the right ICA remains unchanged. Each carotid ultrasound report was undertaken at the same location but was reported by a different radiologist and undertaken by different ultrasound technologists. There is currently no

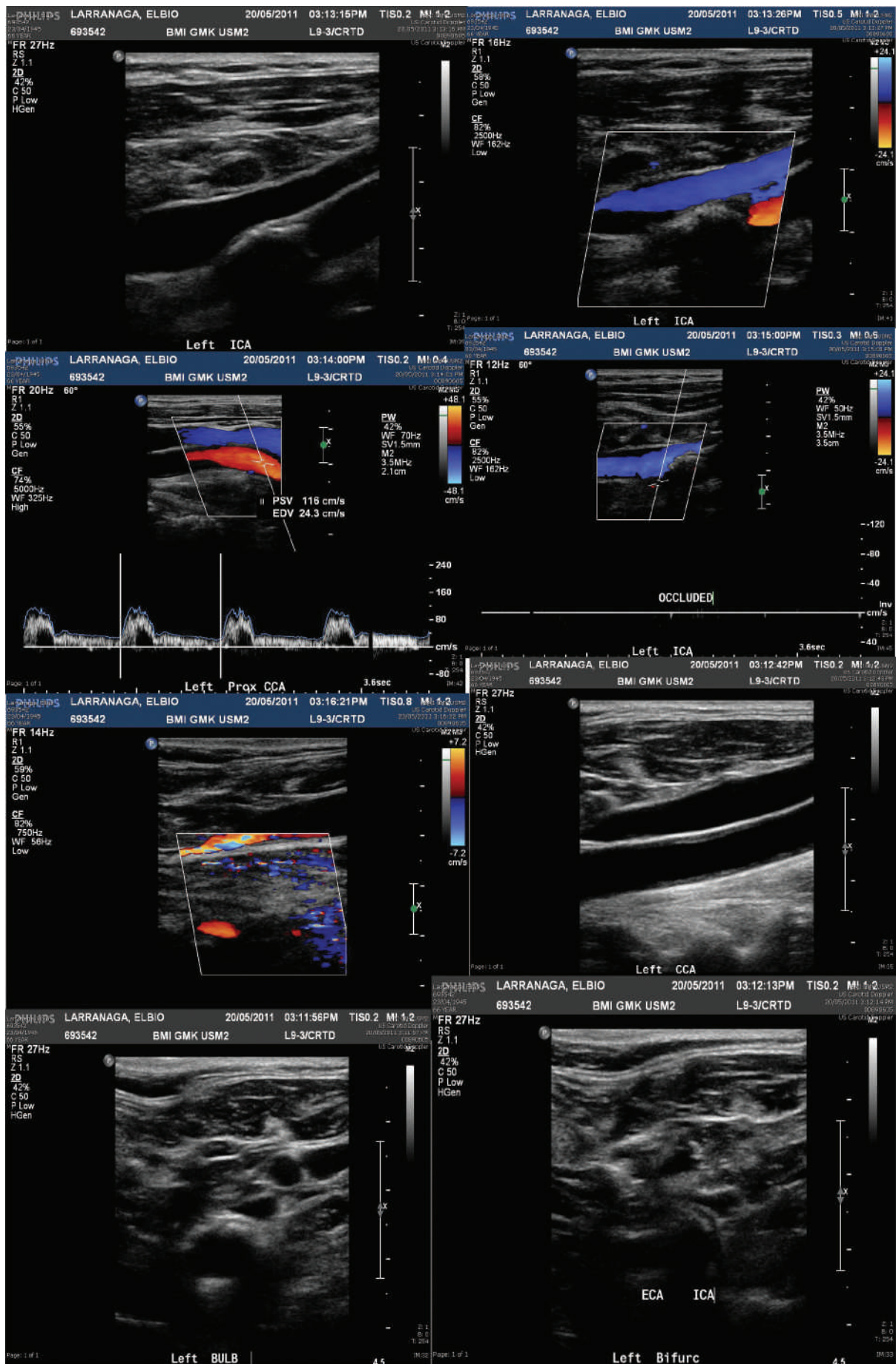
explanation or clear aetiology which can account for the late spontaneous recanalization of Mr EL's left ICA¹.

Mr EL decided not to have any further follow-up or surveillance in regards to his vascular disease and does not want open arterial or endovascular repair should a problem arise in the future. He was subsequently discharged from clinic with no further plans for medical imaging.

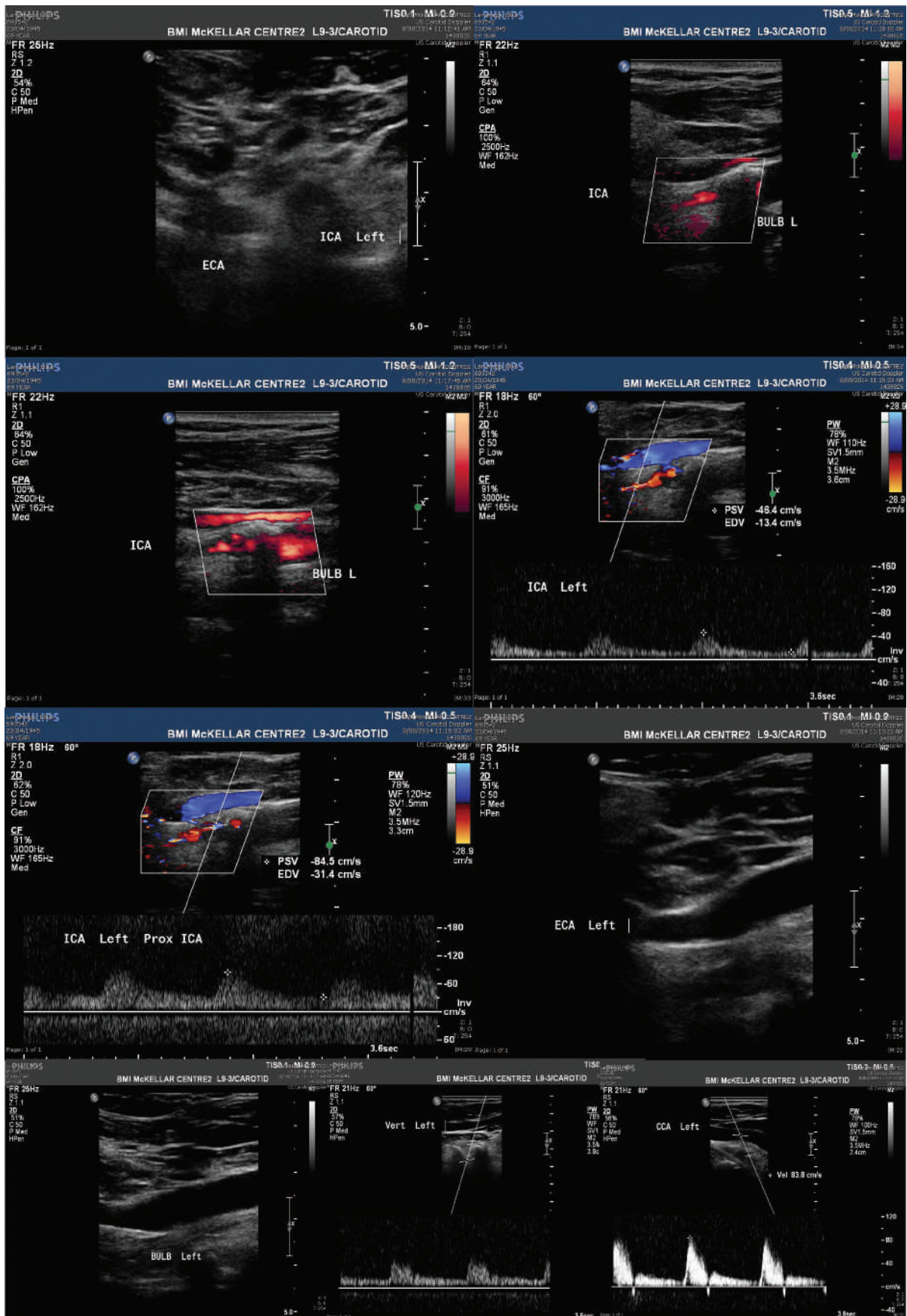
Discussion

Spontaneous recanalization of the internal carotid artery is not uncommon in the acute phase². However late spontaneous recanalization remains rare with only anecdotal evidence including five similar case studies and one prospective cohort study published within the last 10 years^{1,3-5}. The imaging modality during follow-up surveillance is varied with ultrasound (US), magnetic resonance angiogram (MRA) and computerized tomographic angiography (CTA) all routinely used. Despite the increased cost and risk associated with MRA and CTA these are both commonly selected instead of US imaging³. However, a recent study demonstrated that US equals the accuracy of CTA for carotid artery disease surveillance and given its clear advantages should be the imaging modality of choice³.

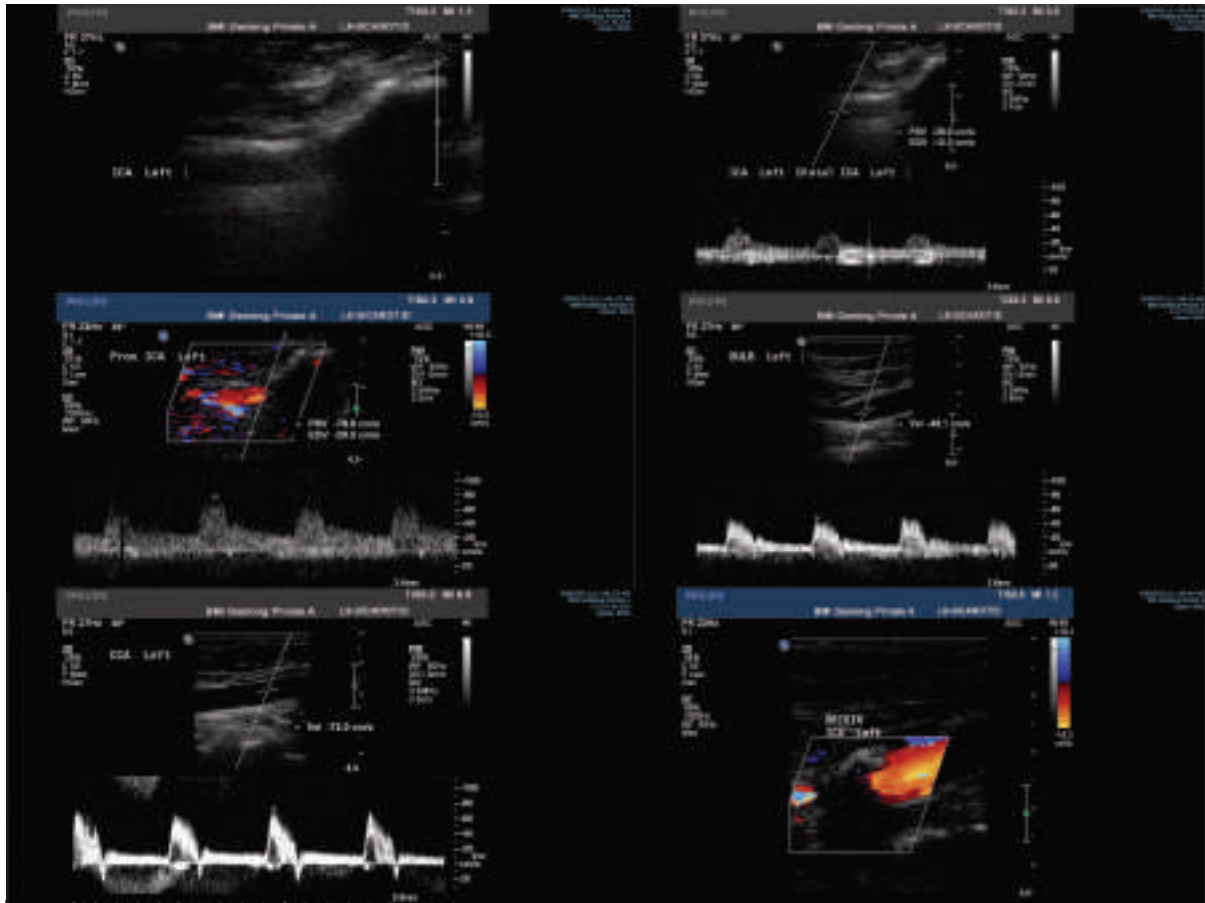
A review of the literature also demonstrates a wide range of clinical followup times for patients with contralateral carotid artery occlusion, which makes assessing the time course of recanalization difficult⁶. However, the likelihood of this occurring does decrease with time, highlighting that older atheroembolic clot is more resistant to recanalization⁶. There are numerous hypotheses to explain spontaneous recanalization in the acute setting; however the aetiology behind chronically occluded carotid arteries remains known¹.



2011 Carotid Ultrasound : The left ICA is completely occluded. No stenosis of the left CCA or origin of the ECA.



2014 Carotid Ultrasound : A normal appearance of the left CCA. Whereas previously the left ICA was thought to be occluded, there appears to be trickle flow through it on today's examination. Normal directional flow of the left vertebral artery.



2015 Carotid Ultrasound : Normal appearance to the left common carotid artery. No visible intimal thickening or plaque. Minor calcified plaque is present at the origin of the internal carotid artery and at the bulb. There are no elevated velocities within the bulb or internal carotid artery.

A prospective study demonstrated acute phase recanalization occurring in up to 33% of patients within 7 days of internal carotid artery occlusion⁵. Further prospective analysis of a larger patient cohort with carotid artery dissection demonstrated that spontaneous recanalization was most likely to occur in the first 6 months⁷. Camporese et al. demonstrated within a sample size of 696 patients with chronic ICA occlusion that only 2.3% (16 patients) would go on to have spontaneous recanalization over 38 months, therefore highlighting the lower rates of recanalization in the late setting³. Within the individual cases studies identified, all five patients underwent successful endarterectomy following late spontaneous recanalization^{1,4,5}. However, the 16 patients identified by Camporese et al. did not undergo further surgical intervention and demonstrated benign clinical outcomes after mean follow-up times of 66.2 months³. This outcome is also reflected in our case study as Mr EL experienced no further neurological symptoms in the 12 months following initial identification of spontaneous recanalization. These findings therefore question the clinical benefit and cost of surgical intervention following late spontaneous recanalization and therefore the benefit of regular surveillance imaging in chronic asymptomatic carotid artery occlusions¹. More research is required to determine the best timeline for follow-up imaging in order to maximise the cost-benefit ratio and avoid potentially unnecessary surgical intervention in patients with internal carotid artery occlusion.

References

- 1) Buslovich S, Hines GL. Spontaneous recanalization of chronic internal carotid artery occlusions: report of 3 cases. *Vascular and endovascular surgery*. 2010.
- 2) Nguyen-Huynh MN, Lev MH, Rordorf G. Spontaneous recanalization of internal carotid artery occlusion. *Stroke*. 2003;34(4):1032-4.
- 3) Camporese G, Labropoulos N, Verlato F, Bernardi E, Ragazzi R, Salmistraro G, et al. Benign outcome of objectively proven spontaneous recanalization of internal carotid artery occlusion. *Journal of vascular surgery*. 2011;53(2):323-9.
- 4) Klonaris C, Alexandrou A, Katsargyris A, Liasis N, Bastounis E. Late spontaneous recanalization of acute internal carotid artery occlusion. *Journal of vascular surgery*. 2006;43(4):844-7.
- 5) Saes GF, Barbosa TCH, Lopes JR, Polimanti AC, Cavalcante RN, Bosch MA, et al. Late spontaneous recanalization of internal carotid artery: case report. *Jornal Vascular Brasileiro*. 2007;6(3):280-3.
- 6) Som S, Schanzer B. Spontaneous recanalization of complete internal carotid artery: A clinical reminder. *Journal of surgical technique and case report*. 2010;2(2).
- 7) Nedeltchev K, Bickel S, Arnold M, Sarikaya H, Georgiadis D, Sturzenegger M, et al. Recanalization of spontaneous carotid artery dissection. *Stroke*. 2009;40(2):499-504.