

# Case Report

## Malignant Mixed Mullerian Tumor of the Uterus

Rijaphin R\*, Kavitha D\*\*, Anoop Sreevalsan\*\*\*, Vasantha N Subbiah\*\*\*\*

\*Assistant Professor, \*\*Senior Resident, \*\*\*Professor, \*\*\*\*Professor & HOD, Department of Obstetrics and Gynaecology, Chettinad Hospital & Research Institute.



Dr. Rijaphin is an undergraduate from Sri Ramachandra Medical College and Research Institute, Chennai. She completed her post graduation (MD) in Obstetrics and Gynaecology from Stanley Medical College and Research Institute, MGR University. She has worked in Government Kasturibha Gandhi Hospital. She is currently working as Assistant Professor in the Department of Obstetrics and Gynaecology, Chettinad Hospital & Research Institute, Chennai, India.

Corresponding author - [Rijaphin.R \(rijaphindr@gmail.com\)](mailto:Rijaphin.R(rijaphindr@gmail.com))

Chettinad Health City Medical Journal 2016; 5(3): 144 - 146

### Abstract

Malignant mixed mullerian tumor of the uterus also called carcinosarcoma is a high grade sarcoma of uterus similar to leiomyosarcoma and undifferentiated uterine sarcoma. Although it is a rare tumor which constitutes about 3-4% of uterine malignancy, it is highly aggressive and contributes to a significant percentage of mortality among uterine malignancy. This malignancy is biphasic, it has two-components both epithelial and stromal (mesenchymal differentiation). The present case is of a 62 year old post-menopausal female who had per vaginal bleeding since 5 months. Ultrasonography revealed thickened endometrium and an ill-defined heterogenous soft tissue mass. Diagnostic curettage was done, which on histopathological examination showed Malignant Mixed Mullerian Tumor with heterologous elements. Panhysterectomy was done, and the diagnosis of Malignant Mixed Mullerian Tumor of the uterus was confirmed.

**Key Words:** Malignant Mixed Mullerian Tumor, Uterus, Postmenopausal.

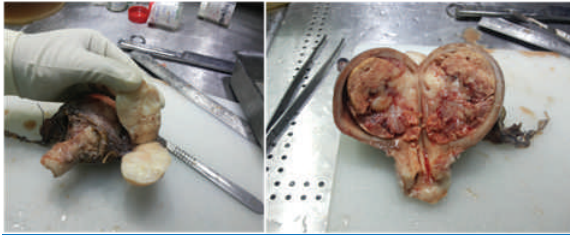
### Introduction

Carcinosarcomas of the uterus are mixed tumors which has both epithelial and mesenchymal components<sup>1</sup>. They contribute to 1/3rd of uterine sarcomas. The most common site of these tumors being endometrium but it can also involve any part of the female genital tract such as ovary, vagina, cervix, vulva, fallopian tube. These malignancies commonly involve the post-menopausal age group although few cases have been reported in younger age group. The clinical features include vaginal bleeding which is abnormal, pain abdomen or pelvic pain and mass on clinical examination. They have a poor prognosis. Some of the poor prognostic factors are advanced stage of the disease, invasion of the myometrium. The stromal / mesenchymal / sarcomatous counter part may be either homologous or heterologous. The heterogenous components can either be a chondrosarcoma or rhabdomyosarcoma or osteosarcoma. Malignant Mixed Mullerian Tumor of the Uterus share the same staging as carcinomas of uterus. This case report is a patient with carcinosarcoma with heterogenous components.

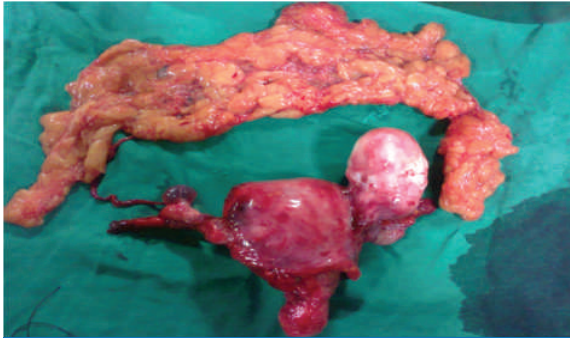
### Case Report

A 62 Year old, multiparous, obese, non hypertensive, non diabetic woman presented with post-menopausal per vaginal bleeding since 5 months, intermittent abdominal pain for 2 months. P/S – cervix healthy, P/V Examination- bulky uterus, mobile, fornices free. Chest X-ray – NAD, USG: - Revealed an ill - defined heterogeneous mass of about 6×4.3 cm in the uterine body, suggesting a possibility of neoplastic pathology.

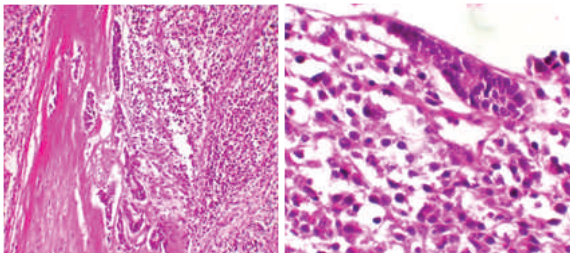
MRI was done - No involvement of myometrium, no nodes, no liver involvement. Diagnostic curettage was done & sample was sent to Department of Pathology for a histopathological examination, which showed a Malignant Mixed Mullerian Tumor with Heterologous Elements. Pre-operative evaluation was done. This was followed by surgery after getting informed consent. Staging laparotomy proceeded to Total Abdominal Hysterectomy with Bilateral Salpingo- Oophorectomy with Bilateral Pelvic lymphadenectomy, infracolic omentectomy, peritoneal biopsies from paracolic areas taken. Intra op findings- No ascites, 50ml peritoneal washings obtained after saline wash, uterus bulky, subserous pedunculated fibroid present, B/L tubes and ovaries normal, omentum appears normal, pelvic lymph nodes normal, paraaortic lymphnodes normal, inferior surface of diaphragm, liver normal. In pathologic evaluation, grossly, the tumor was polypoid, friable with areas of haemorrhages and necrosis measuring 7×5×3.5cm and filling the uterine cavity. Light microscopy of the mass revealed a heterologous malignancy of biphasic type. The epithelial parts of the tumor had glandular component with papillary pattern at places and focal squamous differentiation. Histopathological examination - Malignant mixed mullerian tumor heterogenous type extending to lower uterine segment. Myometrium not involved. 16 Lymph nodes identified - no tumor deposits. Leiomyoma present. parametrium, omentum, peritoneum not involved. Stage of the tumor was 1. As this was an aggressive tumor the patient was referred to Rajiv Gandhi Government hospital for the adjuvant therapy and follow-up.



**Fig 1:** specimen of total abdominal hysterectomy showing polypoidal tumor mass in uterine cavity with haemorrhagic and necrotic areas.



**Fig 2:** Specimen showing uterus with cervix B/L tubes and ovaries and infracolic omentectomy



**Fig 3:** HPE showing both carcinomatous (epithelial) and sarcomatous (mesenchymal /stromal) elements of MMMT with numerous mitotic figures.

## Discussion

Malignant mixed Mullerian tumor of the uterus also called Carcinosarcoma which is the preferred term according to the World Health Organization (WHO) is a biphasic tumor which has both epithelial and malignant mesenchymal counterparts.<sup>2</sup> These malignancies are monoclonal with probably sarcomatous differentiation. They are rare tumors comprising 5% or less of uterine malignancies. Their 5-year survival rate is anywhere between of 5% to 40%. It is commonly seen in postmenopausal age group, but can also rarely occur in younger population, the most prevalent age being 65 years. Although relatively rare, carcinosarcomas of the uterus, and of the gynecologic and urinary tracts in general, are more common than in other sites, such as lung, possibly because the epithelial stem cells are mesodermal in origin. The symptom triad of MMMT are abdominal pain, profuse bleeding per vaginum and expulsion of necrotic tissue.<sup>3</sup> Clinicopathologic data support separation of carcinomas arising in the endometrium into 2 types. The more common type of neoplasm,

type 1, is typically associated with hyperestrogenism, obesity (due to aromatization of androgens into estrogen), and hyperlipidemia, have well or moderately differentiated, typically endometrioid histology, and have a good prognosis (approximately 85%-90% 5-year survival rate). They are frequently associated with PTEN mutations. Type 2 endometrial carcinomas, which represent 10% to 15% of endometrial carcinomas, are typically seen in women without these clinical features. They typically have poorly differentiated endometrioid or serous histology and a worse prognosis (55%-60% 5-year survival rate) and are more often associated with p53 mutations.

Risk factors for carcinosarcoma include obesity, exogenous estrogen use, and nulliparity<sup>3</sup>, similar to that of endometrial carcinoma. Oral contraceptives and smoking are thought to be protective.<sup>4</sup> Some cases may result from prior pelvic radiation.<sup>5,6</sup> There is also an association between long-term tamoxifen treatment and malignant mixed mullerian tumor. Prognosis depends on the tumor stage, depth of myometrial invasion. Inner third of myometrium is involved in 80% of cases and 40% have deep invasion of myometrium. Lymphovascular space invasion is detected in many cases, with extrauterine spread and metastases at the time of presentation. In general, most metastatic deposits and foci of lymphatic and vascular space invasion are composed of the carcinomatous element, with sarcomatous metastases being rare.<sup>7,8</sup>

Treatment includes panhysterectomy with or without pelvic lymphadenectomy. Depending on the surgical staging, grade, histological type, presence of metastasis, lymphovascular space invasion adjuvant radiotherapy and or chemotherapy is planned. Adjuvant radiotherapy including both external beam radiotherapy and intravaginal brachytherapy can be given to postoperative patients in early stage.

## References

- 1) McCluggage WG. Uterine carcinosarcomas (malignant mixed Mullerian tumors) are metaplastic carcinomas. *Int J Gynecol Cancer*. 2002;12(6):687-90.
- 2) Silverberg SG, Major FJ, Blessing JA, Fetter B, Askin FB, Liao SY. Carcinosarcoma (malignant mixed mesodermal tumor) of the uterus. A Gynecologic Oncology Group pathologic study of 203 cases. *Int J Gynecol Pathol*. 1990; 9(1):1-19.
- 3) Rani K, Jenna – Lynn S. Uterine Carcinosarcomas (Malignant Mixed Mullerian Tumors): A review with special emphasis on the controversies in Management. Hindawi Publishing Corporation, Obstetrics & Gynaecology International. 2011; Volume 2011. 13 pages.
- 4) Zelmanowicz A, Hildesheim A, Sherman ME, Sturgeon SR, Kurman RJ, Barrett RJ. Evidence for a common etiology for endometrial carcinomas and malignant mixed mullerian tumors. *Gynecol Oncol*. 1998; 69(3):253-7.

- 5) Ali S, Wells M. Mixed Mullerian tumors of the uterine corpus: a review. *Int J Gynecol Cancer*. 1993;3(1):1-11.
- 6) Pothuri B, Ramondetta L, Martino M, Alektiar K, Eifel PJ, Deavers MT. Development of endometrial cancer after radiation treatment for cervicacarcinoma. *Obstet Gynecol*. 2003;101(5):941-5.
- 7) Bitterman P, Chun B, Kurman RJ. The significance of epithelial differentiation in mixed mesodermal tumors of the uterus. A clinicopathologic and immunohistochemical study. *Am J Surg Pathol*. 1990;14(4):317-28.
- 8) Sreenan JJ, Hart WR. Carcinosarcomas of the female genital tract. A pathologic study of 29 metastatic tumors: further evidence for the dominant role of the epithelial component and the conversion theory of histogenesis. *Am J Surg Pathol*. 1995;19(6):666-74.